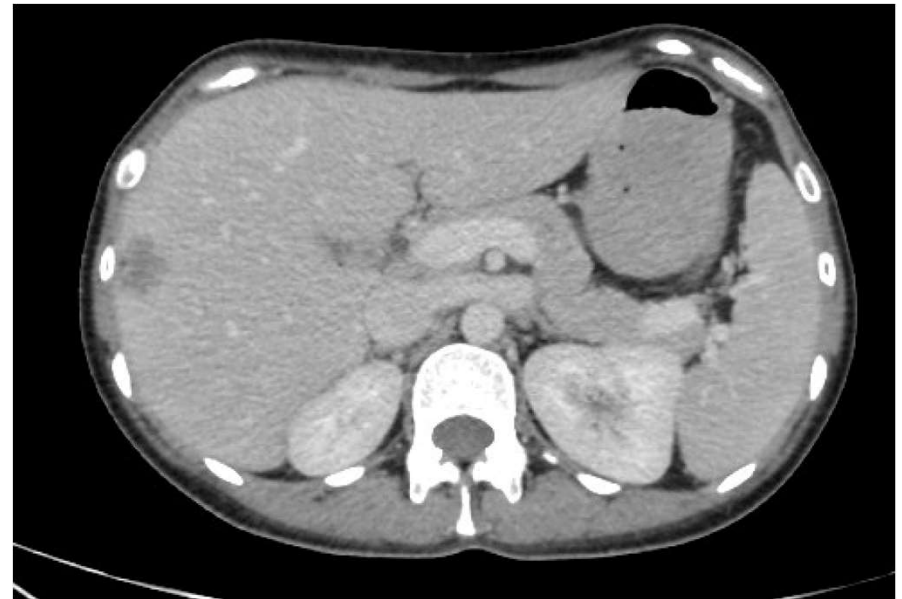
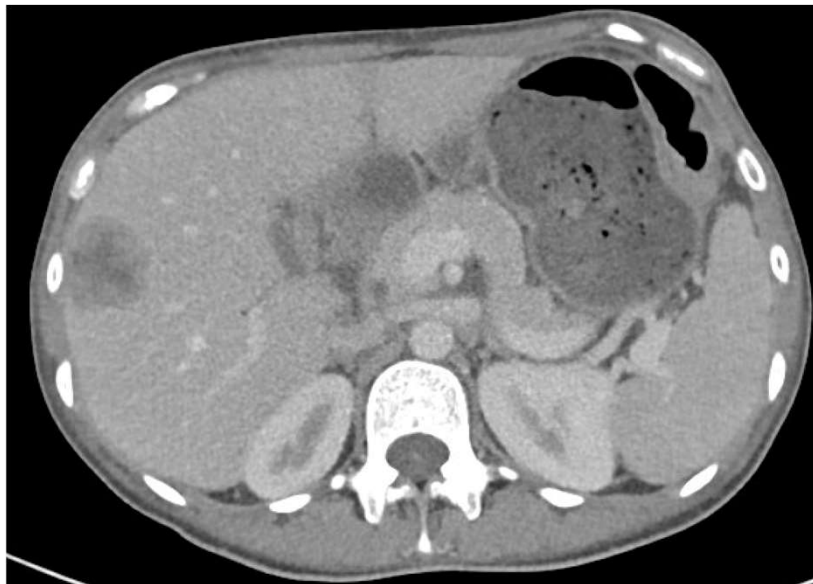
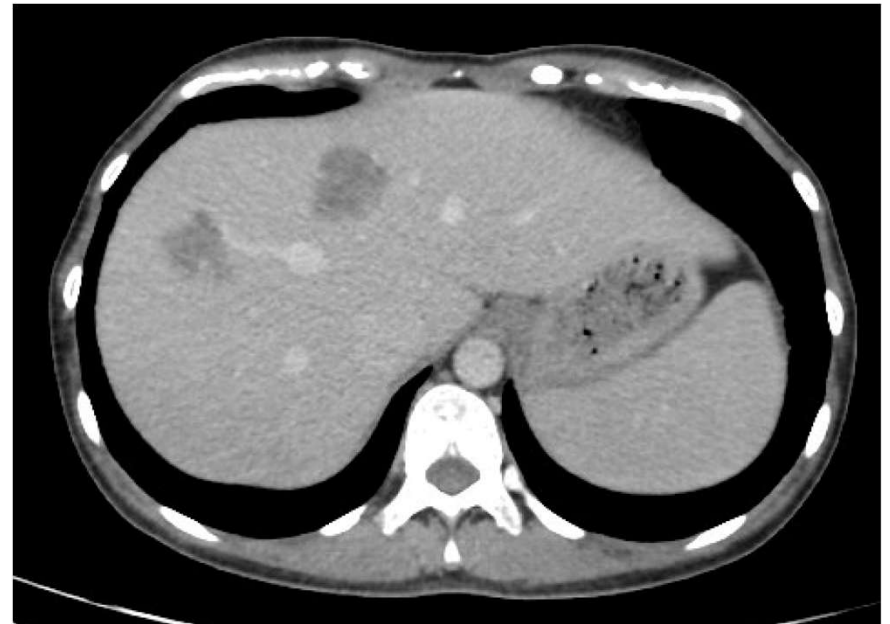
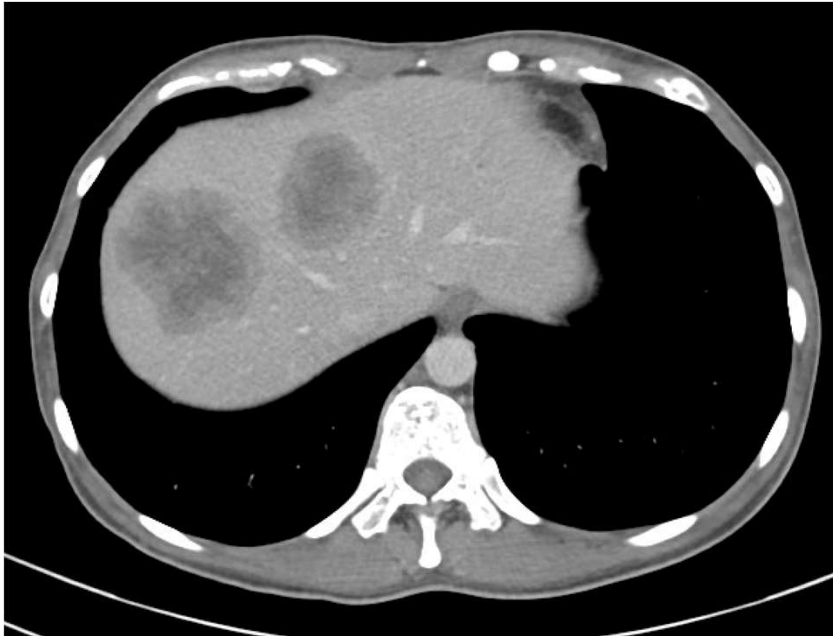# Case Study - Ms A

## Multistaged liver resection

- Initially defunctioned with ileostomy
- Liver first approach
  - “Reverse” order of treatment compared with traditional
- Chemotherapy (FOLFOXIRI + cetuximab) and rectal chemoradiotherapy

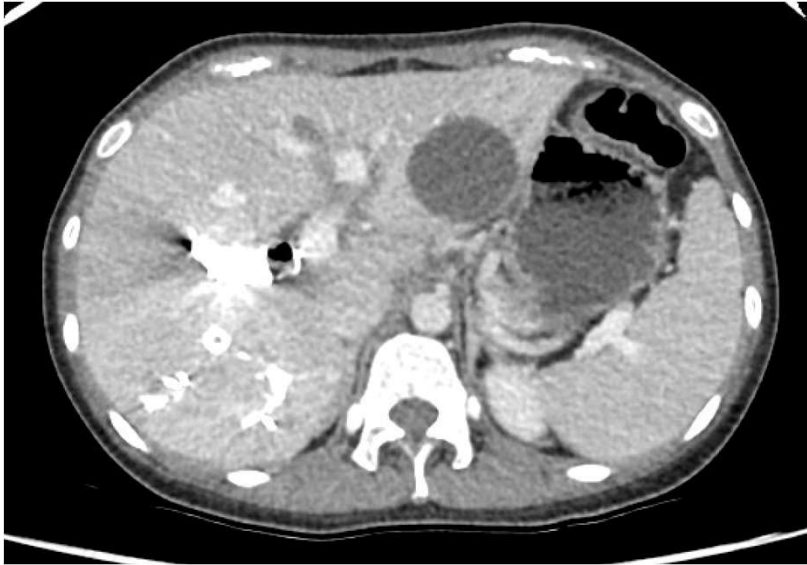# Post chemotherapy



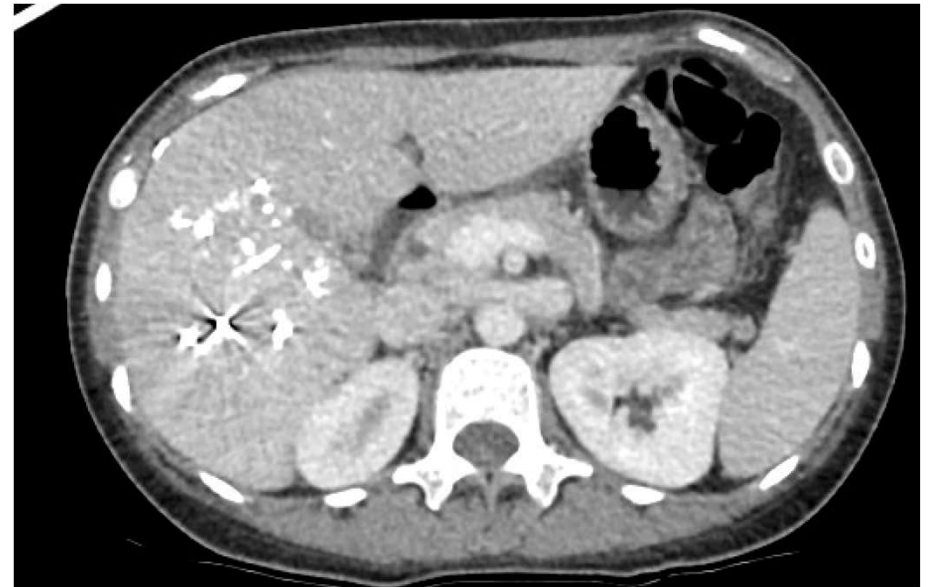
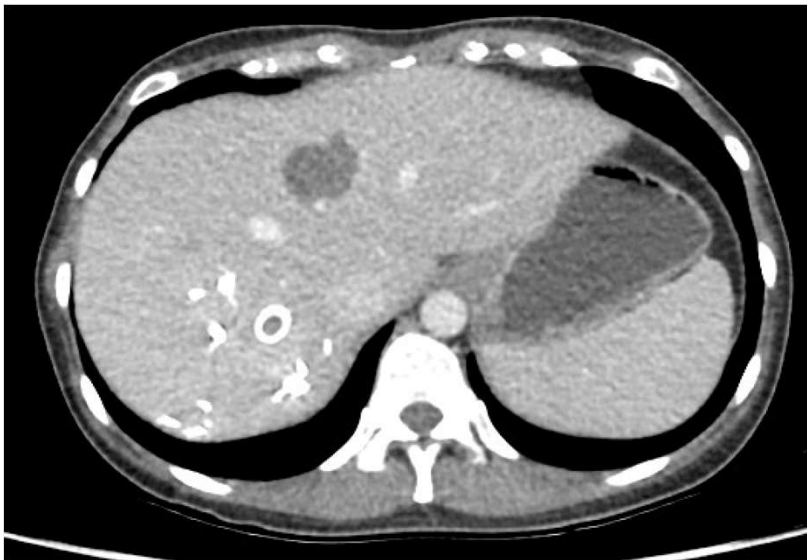# Case Study - Ms A

- April 2021 - percutaneous microwave ablation segment 4a tumour
- April 2021 - Laparoscopic wedge resection segment 3 tumour
- Right portal vein and hepatic vein embolization

# Post 1st round of treatment

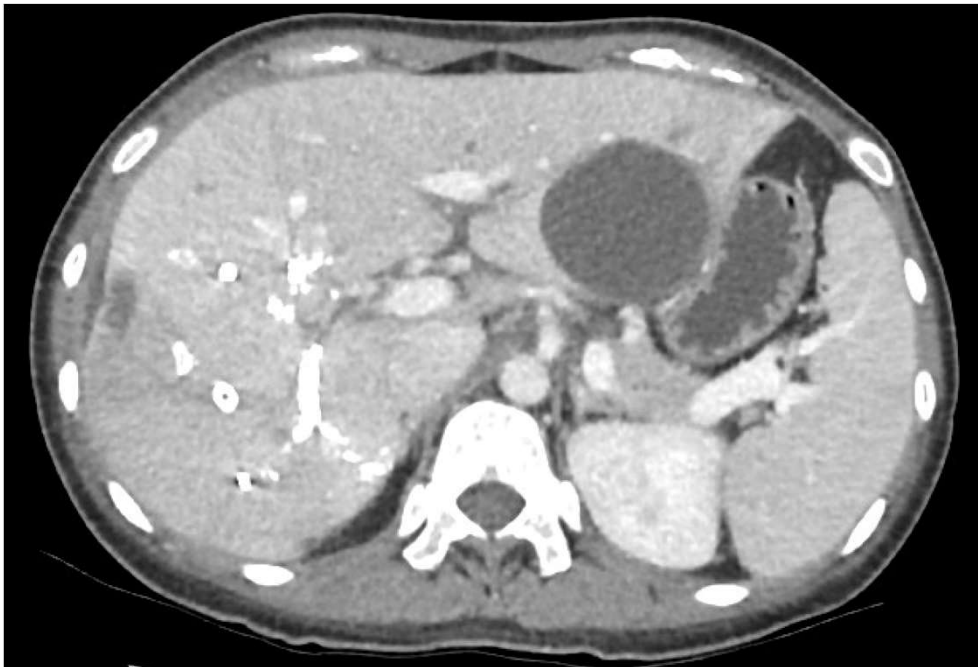

Resection seg 2 met  
Microwave ablation seg 4 met  
Right portal vein and hepatic vein embolization

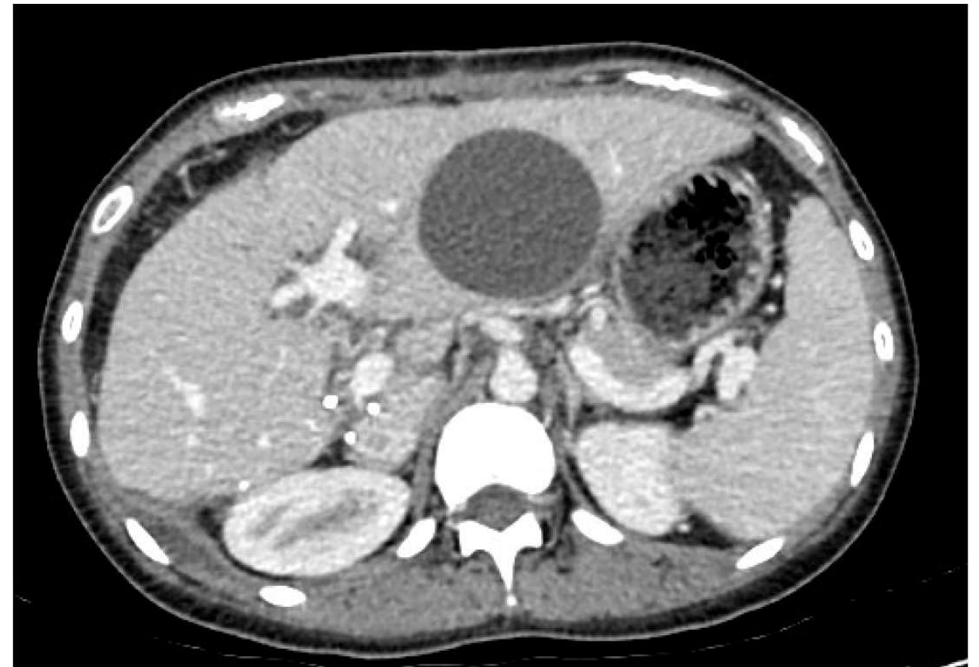


# Case Study - Ms A

- Further ablation of seg 4a tumour
- May 2021 - open right hepatectomy and ablation seg 4a tumour



April 2021



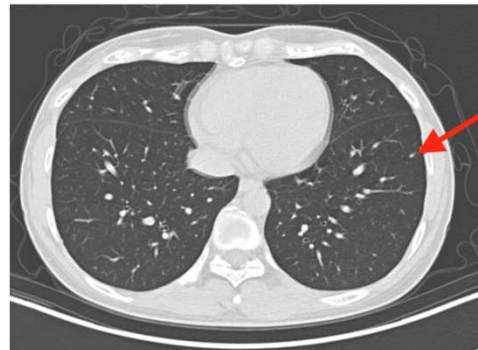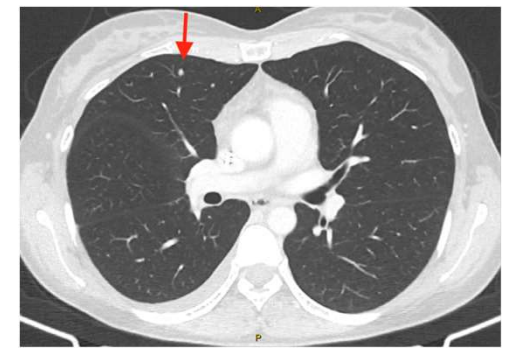
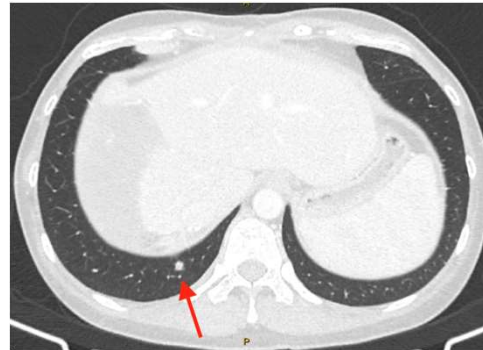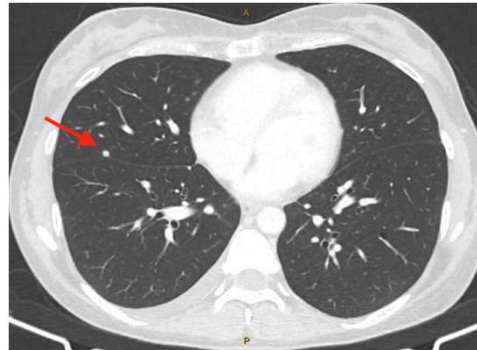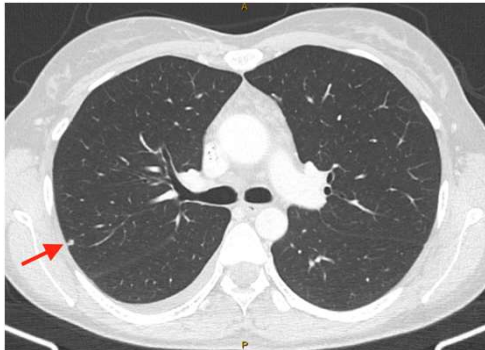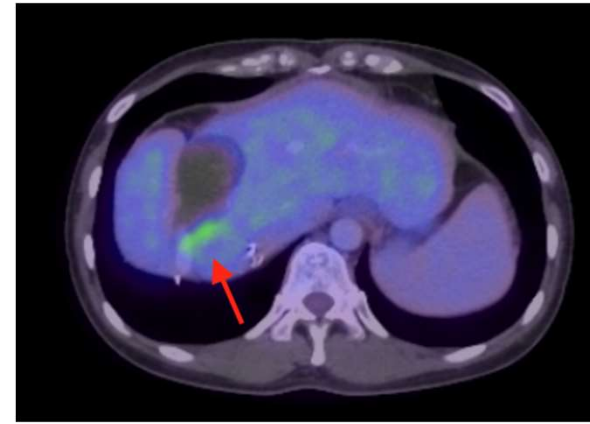
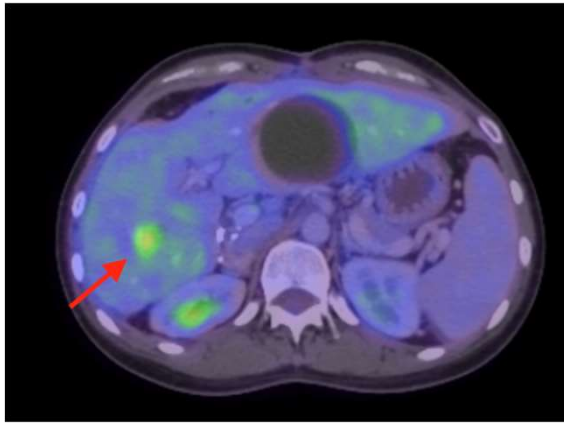
June 2021 - 1 month post right hepatectomy

# Case Study - Ms A

- Sep 2021 - open anterior resection, hysterectomy, bilateral salpingo-oophorectomy, right ureteric and pelvic side wall resection
  - T3N0
- Jan 2022 - ileostomy reversed
- Feb 2022 - recurrence in liver
- Mar 2022 - open ablation of seg 4 met
- Mar-April 2022 - rectal anastomotic leak - defunctioning ileostomy and endosponge

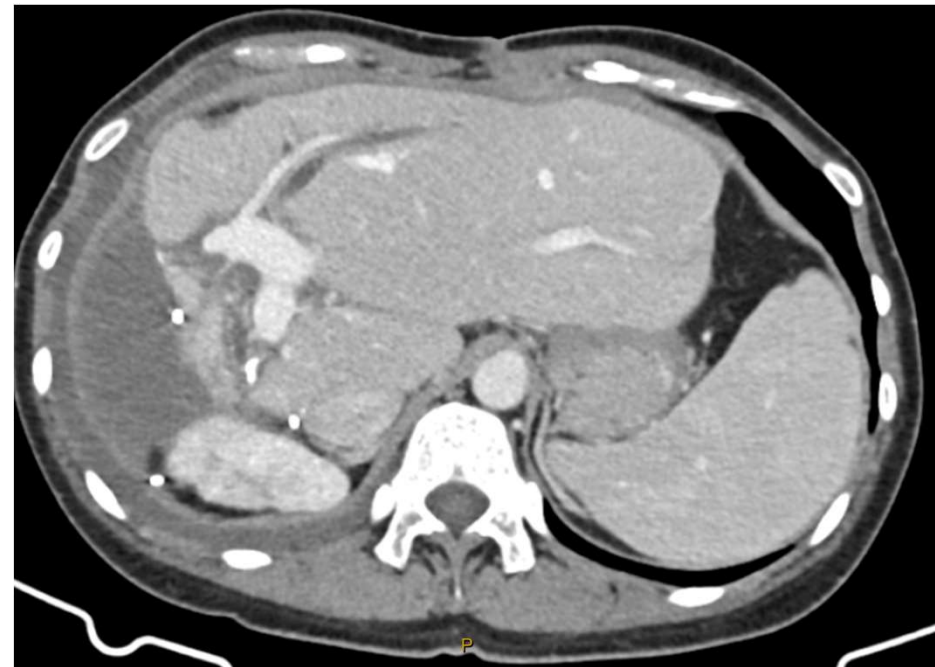
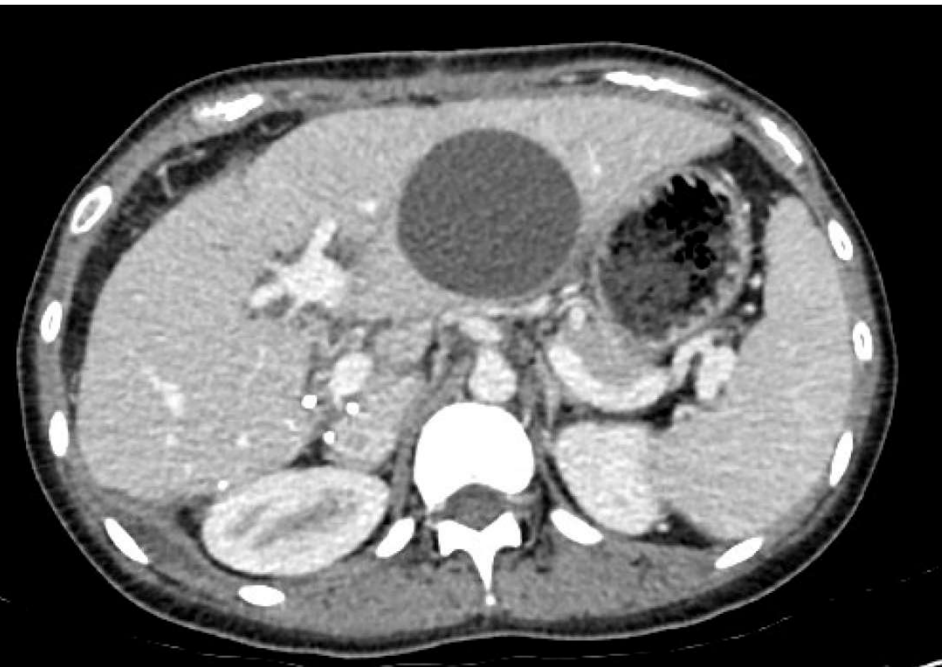
# Case Study - Ms A

- May 2022 - recurrence of liver mets in segment 4, lung mets



# Case Study - Ms A

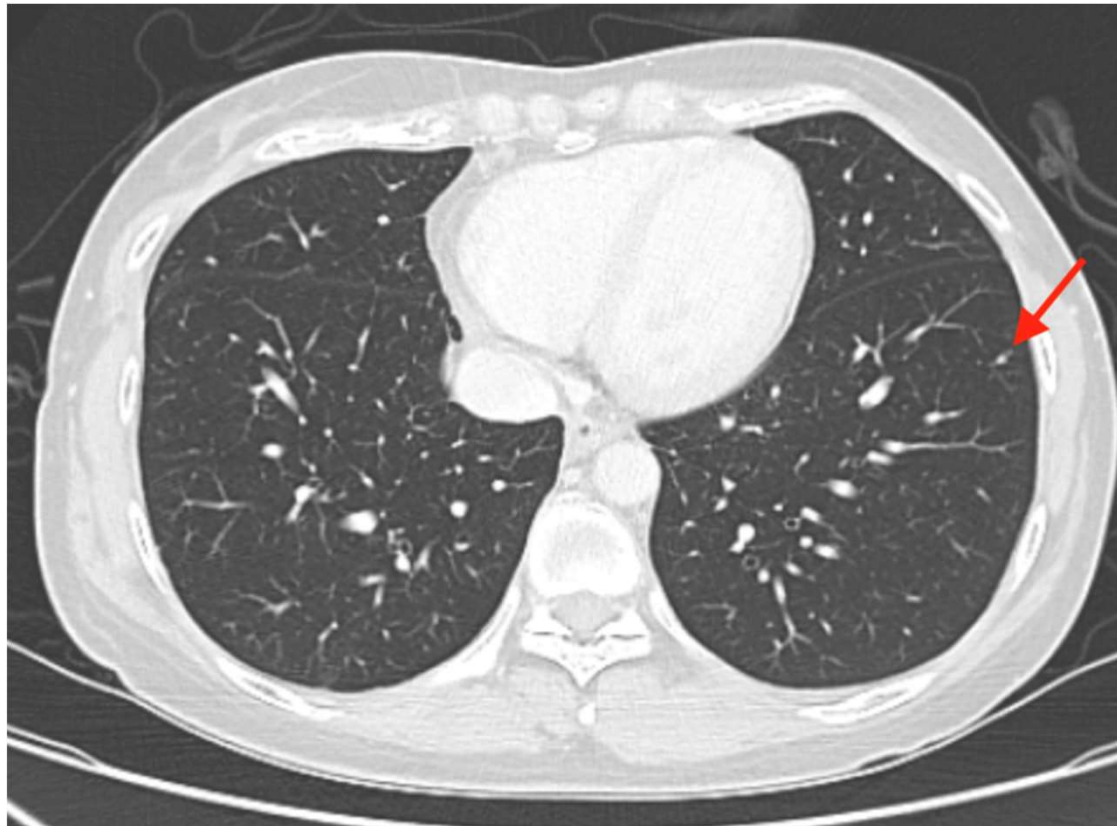
- Chemotherapy - FOLFIRI + cetuximab
- Oct 2022 - Open segment 4 resection





# Case Study - Ms A

- Dec 2022 - R thoracotomy resection multiple lung mets
- Jan 2023 - single possible residual 2mm L lung lesion (too small for surgery yet)



# Case Study - Ms A

- Liver-first approach
- Powerful systemic chemo with biologic
- Multistaged liver resection combined with ablation
- Combined portal vein and hepatic vein embolization
- Laparoscopic liver resection
- Repeat liver resection
- Pelvic exenteration
- Resection of extrahepatic disease