

Pancreatic cysts

Universe Leung

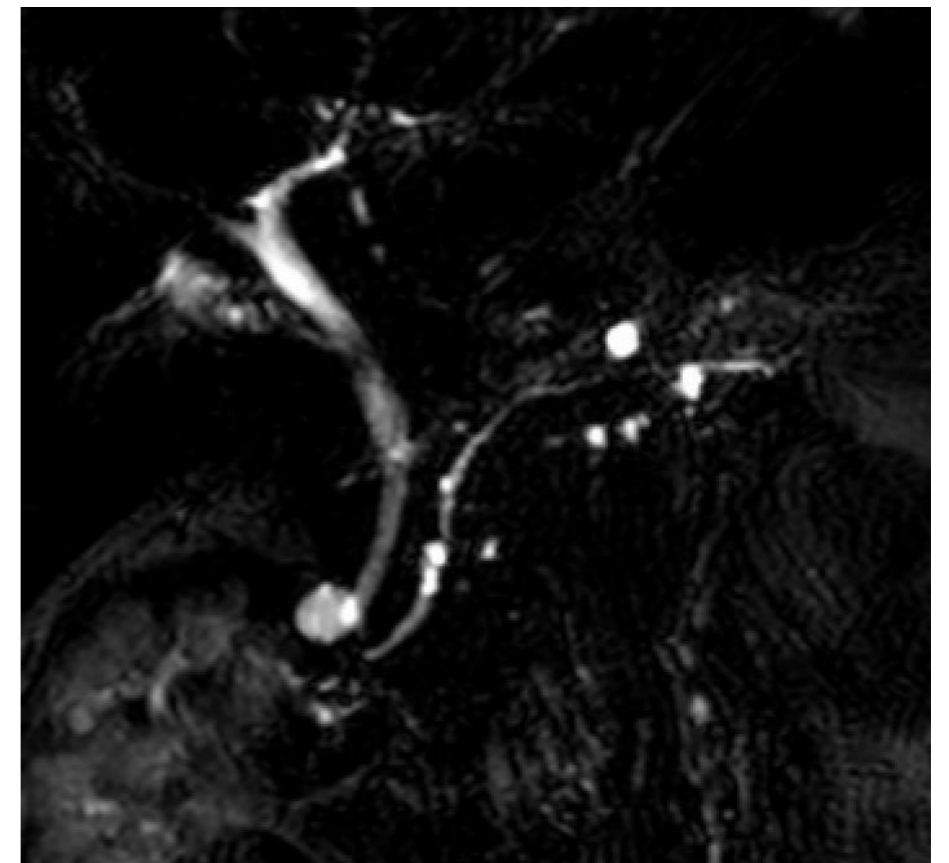
General and Hepatopancreatobiliary Surgeon

Waitemata DHB

Greenlane Medical Specialists

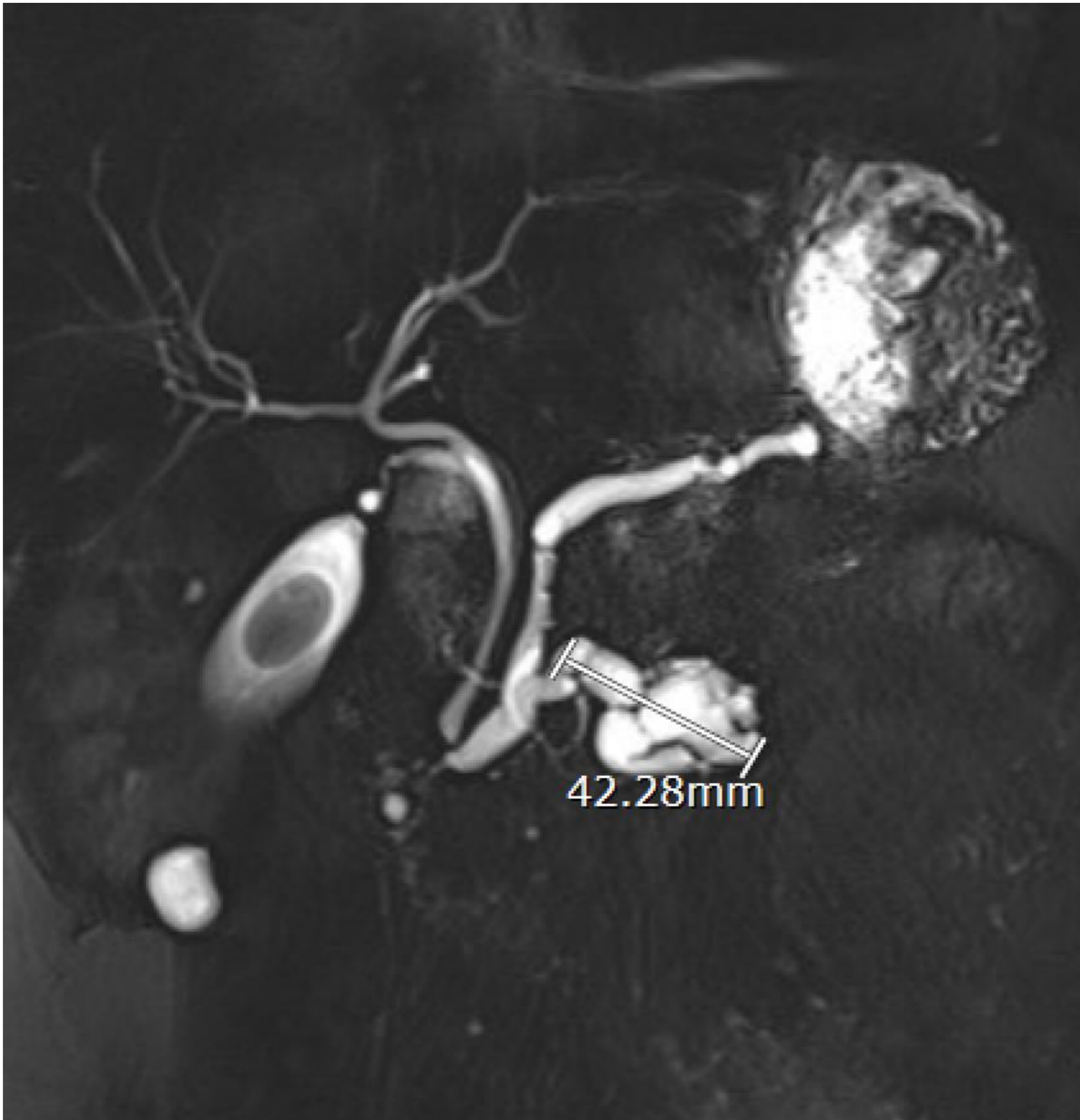Case 5

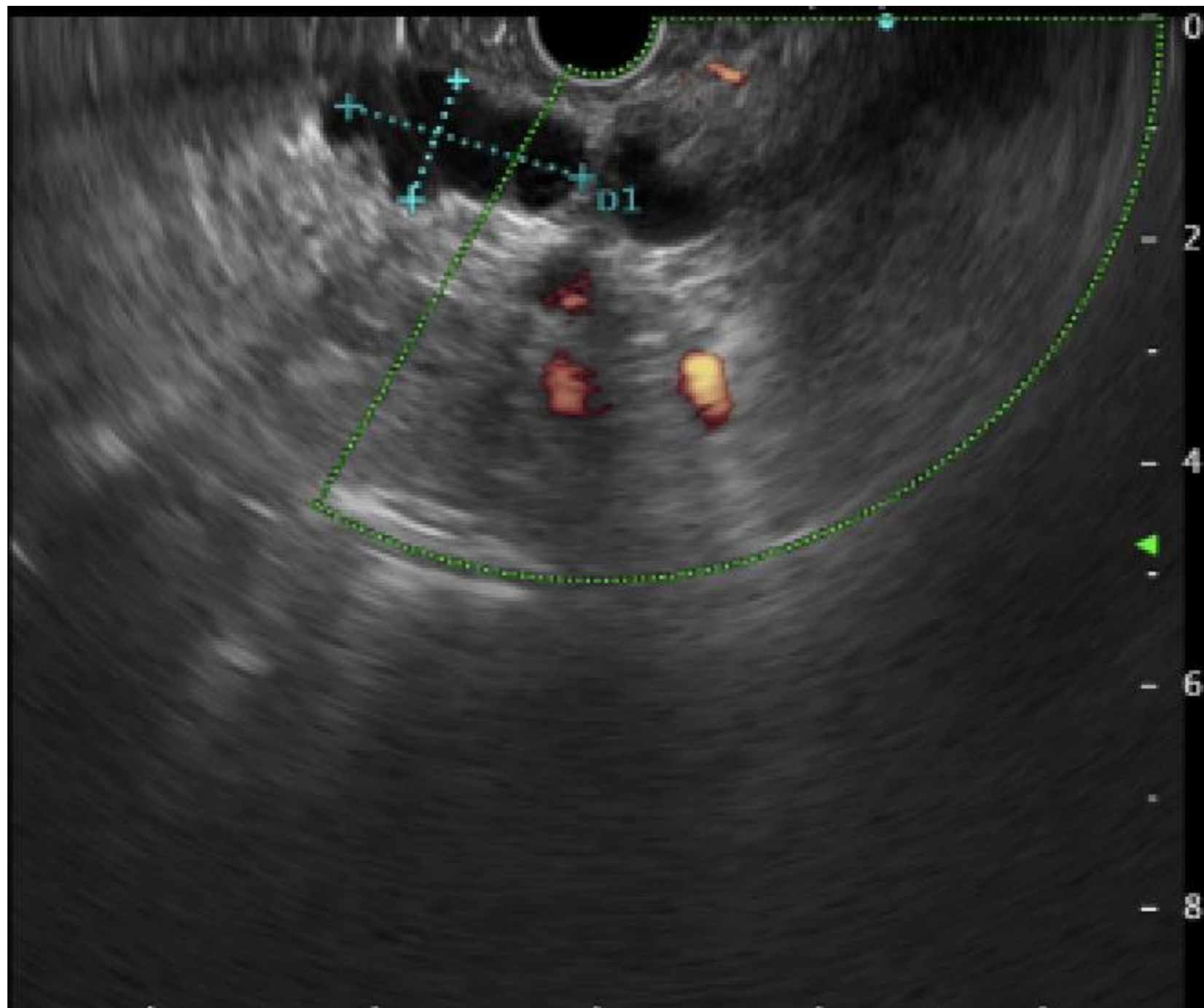
- 71 y.o woman USS for routine health check found small panc cyst
- MRI showed multiple small cysts, largest 10mm, no definite main duct communication, normal sized main panc duct
- Likely multiple small side-branch IPMNs
- MRI in 2 years



Case 6

- 58 y.o. man with incidental panc cyst on liver imaging
- CT and MRI showed 4.6cm uncinatae cyst and adjacent main duct 7mm
- EUS showed no nodules or wall thickening





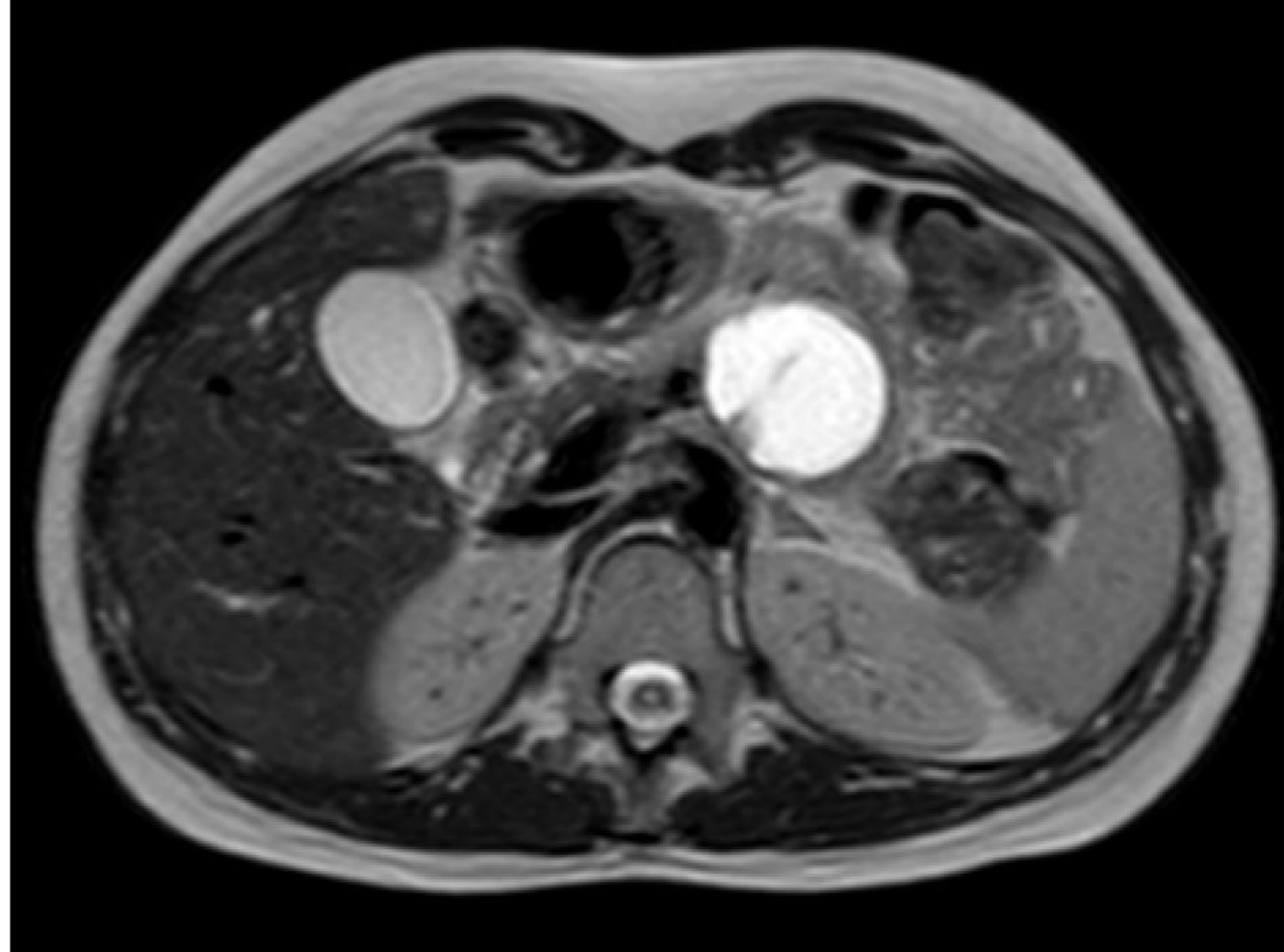
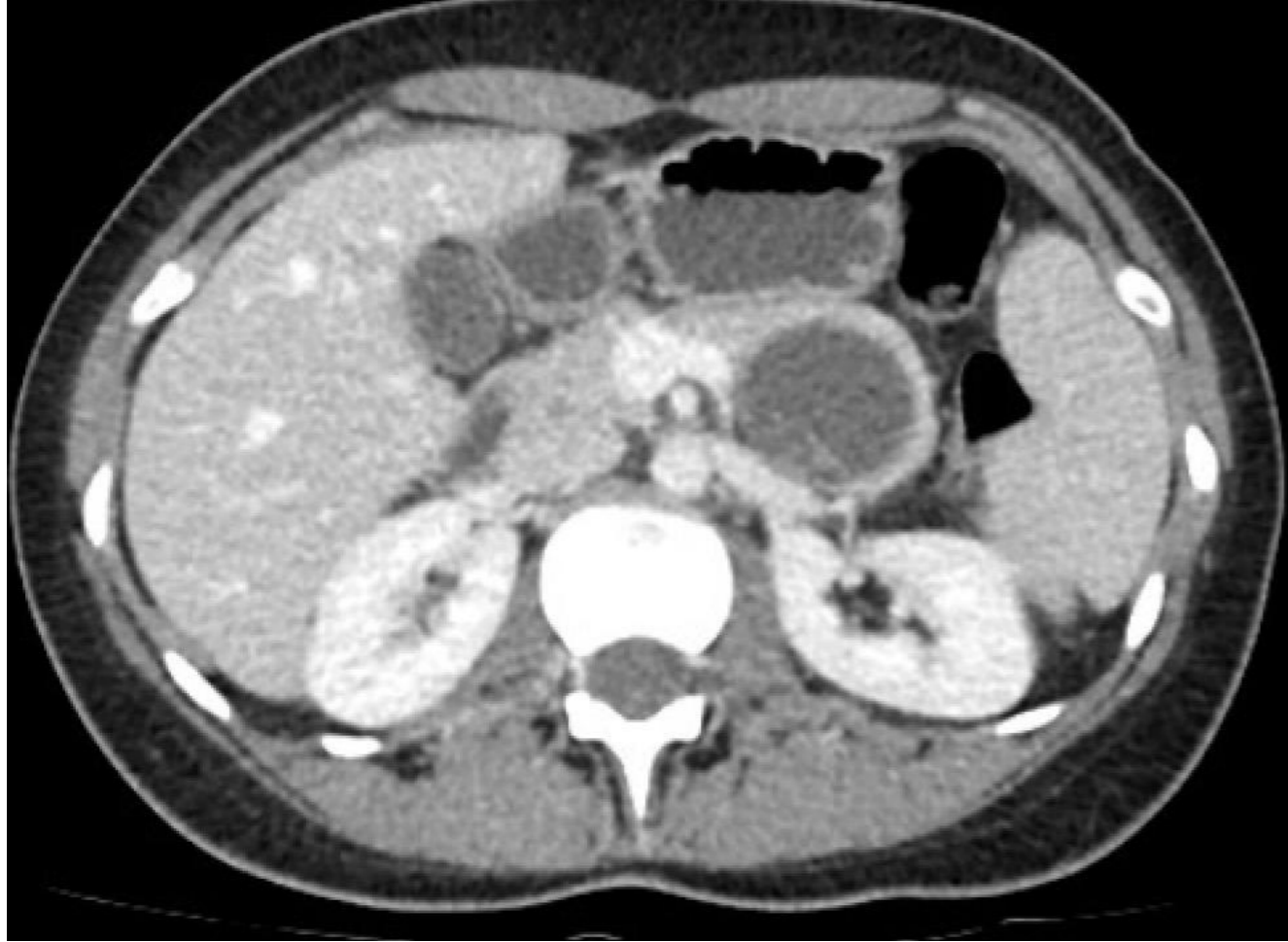FNA - mucin, insufficient sample for biochem

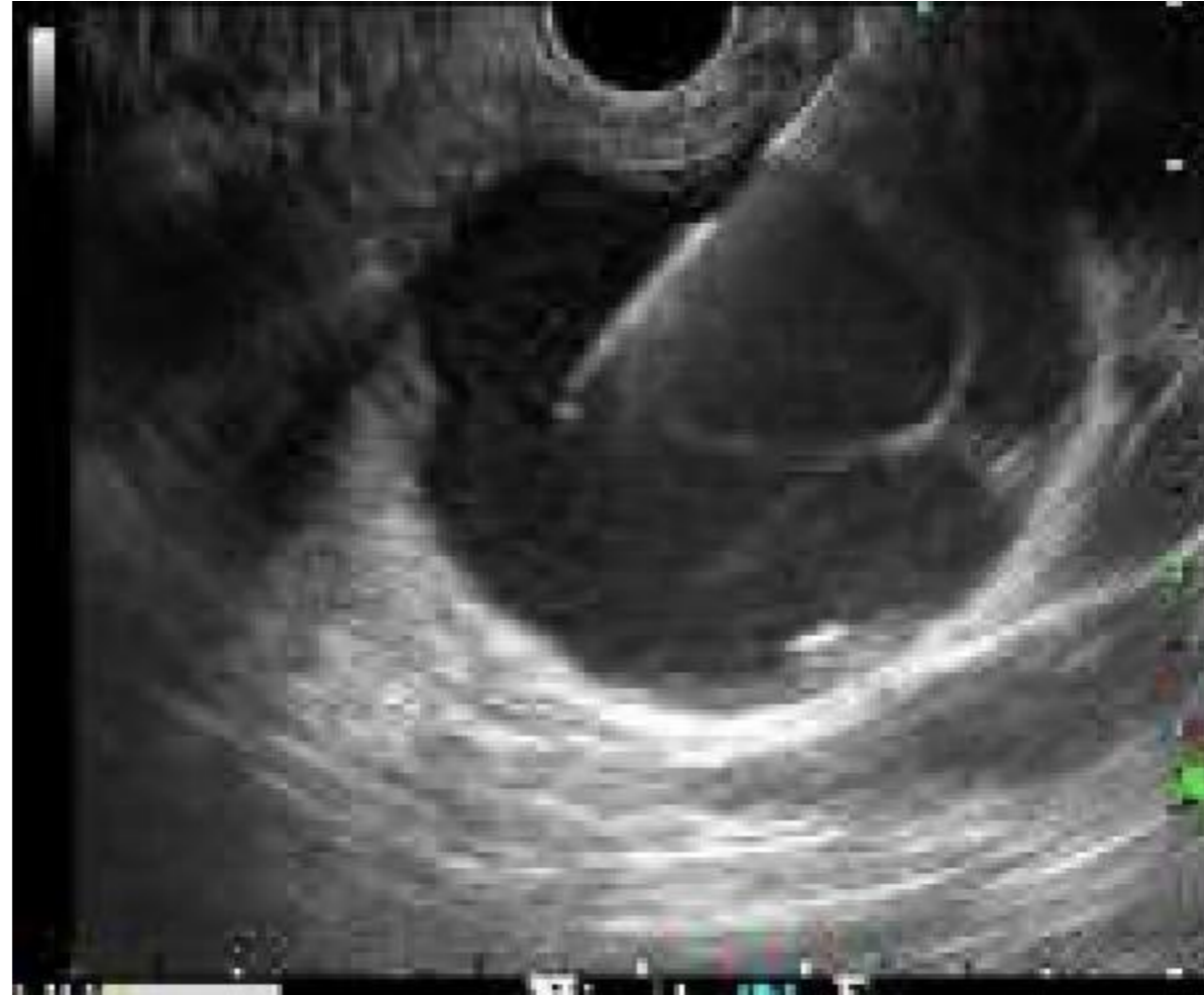Case 6

- Likely mixed-type IPMN
- Awaiting laparoscopic whipple

Case 7

- 26 y.o. woman with 2 episodes of mild pancreatitis
- USS and CT showed 4.5cm cyst in tail of panc
- MRI showed thin walled septated cyst, no nodules, normal size main pancreatic duct
- EUS showed thin walled cyst





13/04/21
11:23

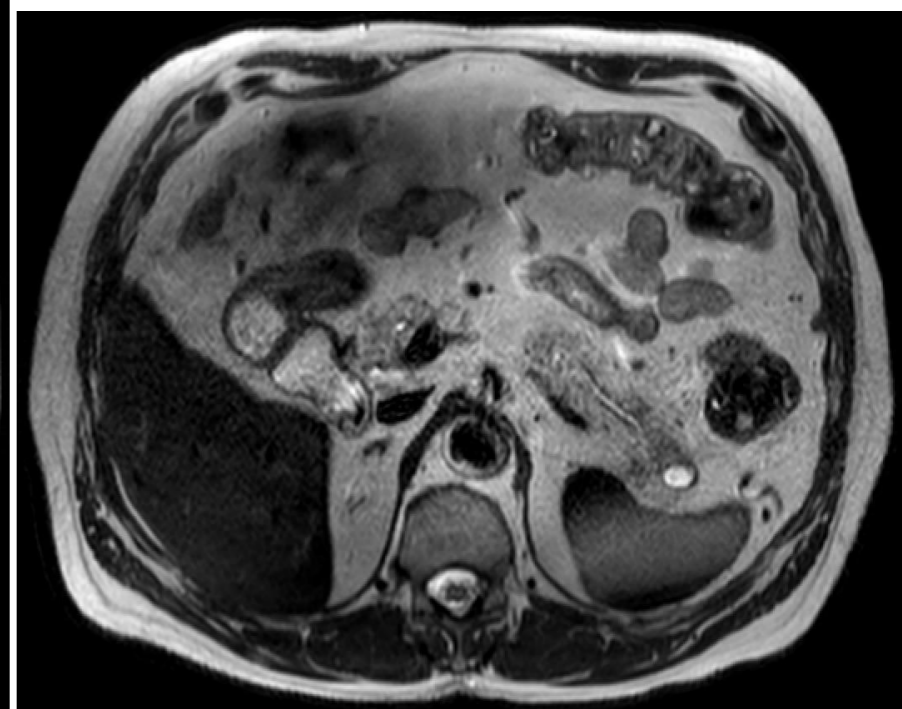
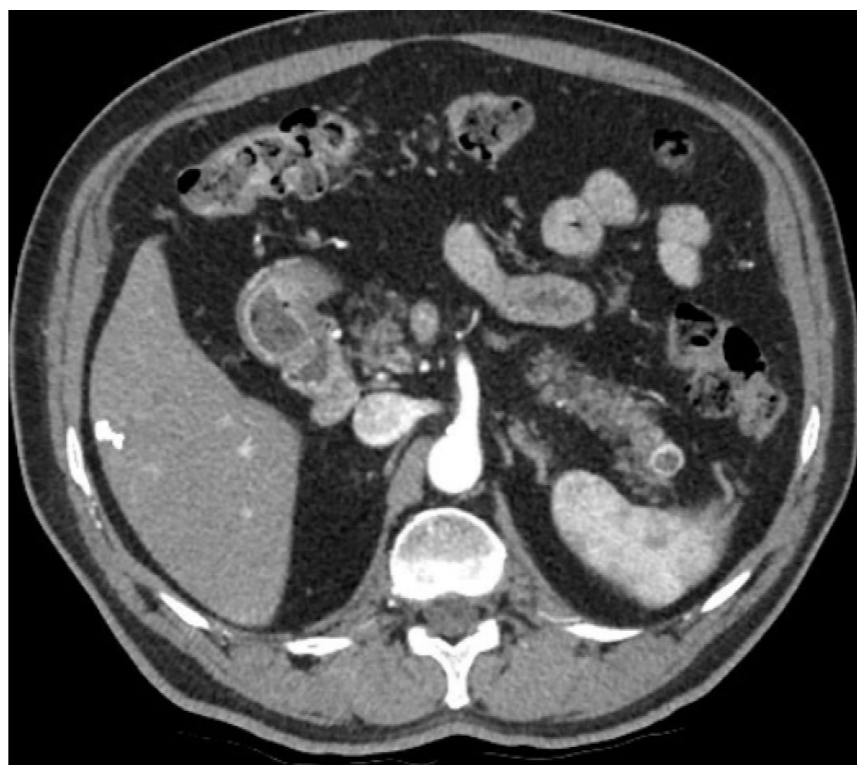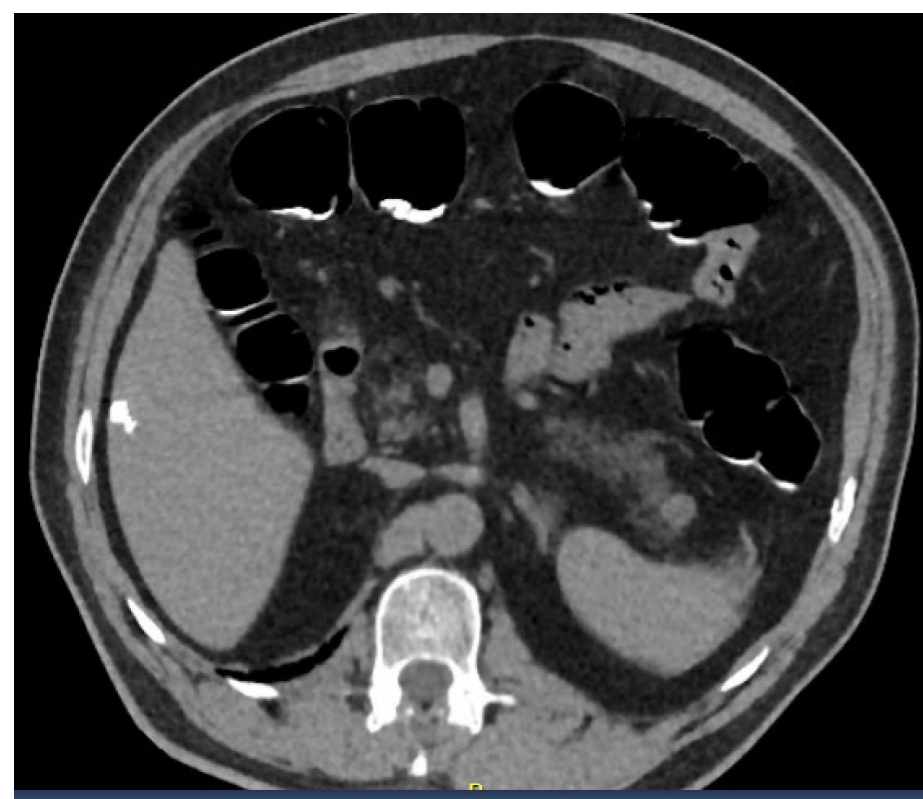
| | |
|--------------------------------|-----------------|
| Specimen type | Pancreatic cyst |
| Amylase other | >6500 |
| Authorised by | Sarah Li, MLS |
| Other Carcinoembryonic Antigen | 316.3 |

Case 7

- Differentials include mucinous cystadenoma, IPMN, and pseudocyst
- Awaiting distal pancreatectomy

Case 8

- 83 y.o man with incidental tail of panc cyst on CT colonography
- CT showed arterial rim enhancement
- MRI - cystic



Case 8

- Likely cystic neuroendocrine tumour 14mm
- For observation (consider resection if size >2cm)